

RECONSTRUCTION OF SEVERELY DAMAGED ENDODONTICALLY TREATED AND BLEACHED TEETH USING A MICROHYBRID COMPOSITE RESIN: TWO-YEAR CASE REPORT

Simone Deliperi, DDS*
David N. Bardwell, DMD, MS†
M. Debora Congiu, DDS‡

Clinical indications for direct composite restorations have expanded in the last decade, primarily due to improved physical, aesthetic, and handling properties. As a consequence, their increased predictability has encouraged clinicians to progressively abandon amalgam. This article presents a clinical protocol to reconstruct severely damaged endodontically treated and bleached anterior teeth with particular emphasis on placement and curing techniques. Common complications encountered during the bonding of teeth that have undergone endodontic and bleaching treatments are also analyzed.

Learning Objectives:

This article presents a clinical modality to reconstruct severely damaged endodontically treated and bleached anterior teeth, with particular emphasis on placement and curing techniques. Upon reading this article, the reader should:

- Understand the clinical parameters for aesthetic treatment of endodontically treated teeth.
- Recognize the layering technique used for direct composite restorations.

Key Words: composites, microhybrid, direct, aesthetic

*Visiting Instructor and Research Associate, Tufts University School of Dental Medicine, Boston, Massachusetts; Faculty, Department of Restorative Dentistry, University of Cagliari, Italy.

†Associate Clinical Professor of Restorative Dentistry and Director, Post Graduate Esthetic Dentistry, Tufts University School of Dental Medicine, Boston, Massachusetts.

‡Private practice, Cagliari, Italy.

Simone Deliperi, DDS
Via G. Baccelli, 10/b
09126 Cagliari-Italy

Tel: 011-390-34-79-533-259

Fax: 011-390-70-497-293

E-mail: sdeliperi@hotmail.com

The introduction of nightguard vital bleaching (NGVB) in 1989 significantly contributed to the growth of aesthetic dentistry.¹ Tooth whitening is a painless procedure that does not require the administration of anesthesia, thus encouraging patients to seek additional aesthetic treatment. Moreover, the noticeable color change observed following whitening procedures may motivate patients to seek further aesthetic treatments (eg, porcelain or resin bonded composite [RBC] restorations). In particular, RBCs represent an ideal compromise of aesthetics, longevity, and reduced expenditure when compared to porcelain alternatives. The development of composite resins with improved physical, aesthetic, and handling properties, as well as the introduction of newer-generation adhesive systems, are primarily responsible for their increasing durability and reliability.²⁻⁶

As a consequence, the clinical indications for RBCs have been expanded in the last decade.⁷ The increase in patient demand for conservative treatment options to preserve sound tooth structures can be satisfied using direct composite systems. The literature has further indicated that modern adhesive systems — in combination with RBCs — can also reinforce the remaining tooth structure.⁸⁻¹⁰ These findings have encouraged clinicians to restore nonvital teeth by using composite materials to replace only the missing tooth structure in a minimally invasive manner. The mechanism of dentin bonding to

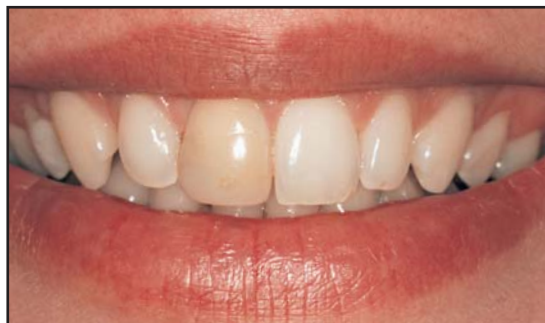

Figure 1. Preoperative smile evaluation demonstrated discoloration on tooth #8(11).

endodontically treated teeth and the longevity of this bond, however, have yet to be explored.¹¹ Similarly, insufficient data are available regarding the clinical performance of adhesive systems when used in previously whitened teeth. Conversely, the literature has indicated that restorative procedures should be delayed for 10 to 14 days in order to better match the bleached tooth structure and avoid alterations in marginal seal and bond strength.¹² This article demonstrates a clinical technique for the direct restoration of severely damaged anterior teeth following extensive endodontic and bleaching treatments.

Case Presentation

A 26-year-old female patient presented with an unaesthetic right maxillary central incisor (Figure 1). The tooth had been restored with an RBC 8 years previously and had progressively discolored over time. Since cold and electronic pulp testing revealed a lack of vitality, endodontic therapy was initiated (Figure 2). Although the advantages of porcelain versus RBC restorations were delineated to inform the patient that the remaining tooth structure might not be sufficient for predictable composite restoration, the patient declined treatment with a bonded fiber post and porcelain crown. Informed consent was secured; the increased expense and chairtime associated with a prosthetic solution combined with the desire to maintain residual tooth structure, justified the patient's choice. An alternative treatment plan including whitening of tooth #8(11) and subsequent restoration with a microhybrid composite resin was proposed. Using the microhybrid composite resin to create symmetry and harmony between the central incisors, mesial and distal reshaping of tooth #9(21) was also recommended.

Clinical Technique

A preliminary alginate impression was taken, and a diagnostic waxup was completed to reproduce the symmetry between the central incisors. A silicone template was fabricated to register the lingual and incisal edges. Shade evaluation was performed, and it was determined that tooth #8 was darker than A4 and tooth #9 was slightly lighter than A1 (Figure 3). Tooth whitening was accomplished using a combination of in-office and at-home bleaching. Gutta-percha was removed 1 mm below the crown prior to whitening, and a barrier was placed at the cemento-enamel junction using a resin-modified glass-ionomer material (eg, Vitrebond, 3M ESPE, St. Paul, MN; Fuji Lining LC, GC America, Alsip, IL) that was light cured for 40 seconds. Tooth whitening was initiated using a chairside bleaching agent following the placement of a light-cured resin barrier (eg, OpalDam, Ultradent Products, South Jordan, UT; Paint

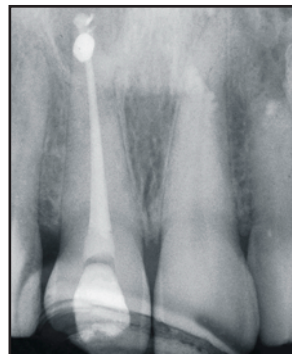


Figure 2. Radiograph of tooth #8 following endodontic treatment.

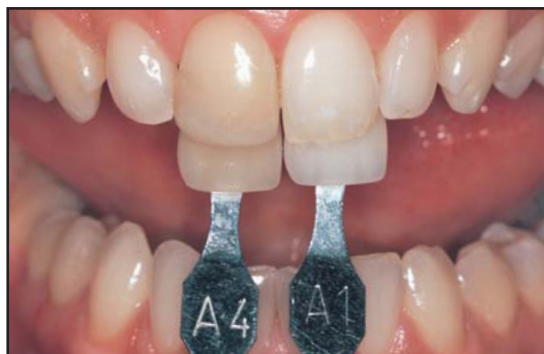

Figure 3. The shades of the central incisors were recorded (Vita, Vident, Brea, CA).

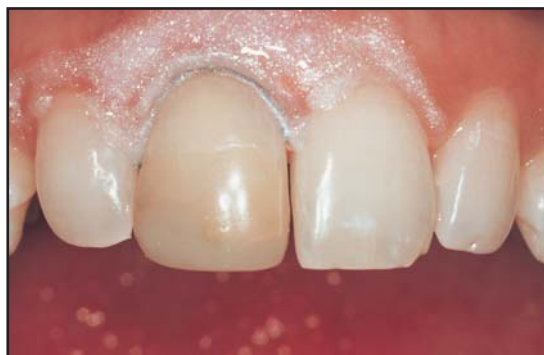

Figure 4. Following gingival retraction, a resin barrier was placed and chairside bleaching was initiated.

On Dental Dam, Den-Mat, Santa Maria, CA) in order to protect the gingival tissues. A #1 retraction cord (eg, Ultrapak, Ultradent Products, South Jordan, UT; Crown Pak, Gingi-Pak, Camarillo, CA) was also used in order to slightly displace gingival tissues and ensure contact of the bleaching agent through to the subgingival portion of the crown (Figure 4). A 35% hydrogen peroxide gel (eg, Opalescence Xtra, Ultradent Products, South Jordan, UT; Hi-Lite, Shofu, Menlo Park, CA; Zoom, Discus Dental, Culver City, CA) was then placed either in the pulp chamber or facial surface of tooth #8 for 30 minutes, refreshing the bleaching solution every 10 minutes.

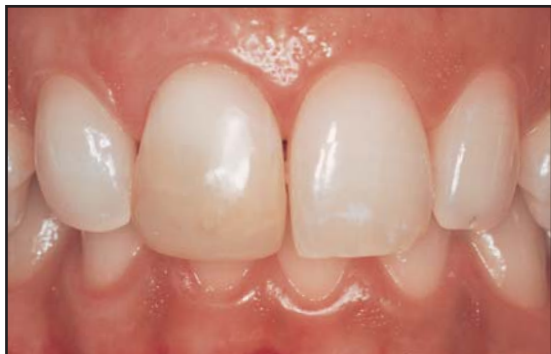

Figure 5. A significant change in shade was observed on tooth #8 once tooth whitening was completed.

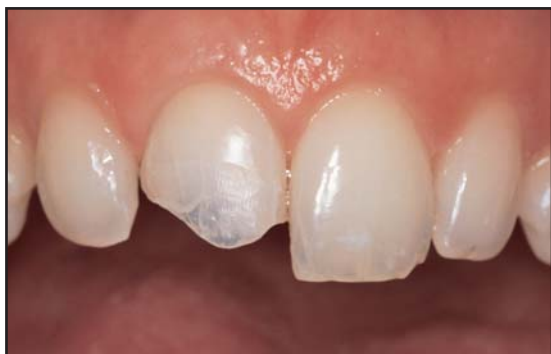

Figure 6. Facial view following removal of the existing composite restoration.

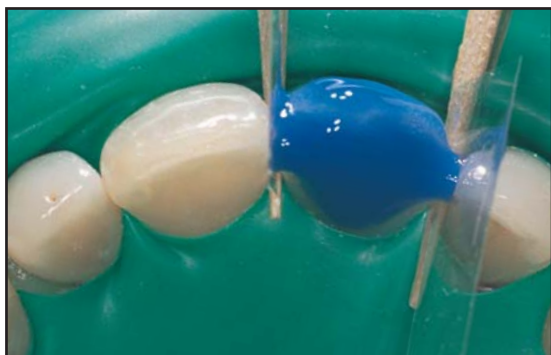


Figure 7. Tooth #8 was etched with 35% phosphoric acid.

Tooth color change was maintained and improved with an at-home whitening program using a 10% carbamide peroxide gel (eg, Opalescence, Ultradent Products, South Jordan, UT; Vivastyle, Ivoclar Vivadent, Amherst, NY) for two weeks following an inside/outside bleaching technique (Figure 5).¹³

Once a correct shade match with tooth #9 was achieved, the treatment was delayed for two weeks in order to better match the adjacent tooth structure and avoid the oxygen inhibition of the adhesive and composite resins. The existing composite resin was completely removed, and a thin enamel shell was preserved to

create an acceptable microhybrid composite resin bond (Figure 6).

A rubber dam was placed and tooth preparation was completed using #2 and #4 burs (eg, Brasseler, Savannah, GA; Axis Dental, Irving, TX) to create rounded line angles. A 1-mm bevel was placed on the facial surface with a #7104 bur (Brasseler, Savannah, GA). The cavity preparation was disinfected with a 2% chlorhexidine antibacterial solution (eg, Consepsis, Ultradent Products, South Jordan, UT; Cavity Cleanser, Bisco, Inc, Schaumburg, IL), and the tooth was etched for 15 seconds using a 35% phosphoric acid (eg, UltraEtch, Ultradent Products, South Jordan, UT; Enamel Etch, Cosmedent, Chicago, IL; Total Etch, Ivoclar Vivadent, Amherst, NY) (Figure 7). The etchant was removed, and the preparation was irrigated for 30 seconds. An adhesive agent (eg, PQ1, Ultradent Products, South Jordan, UT; Optibond, Kerr/Sybron, Orange, CA) was placed in the preparation, gently air thinned until the milky appearance disappeared, and light cured for 20 seconds on the facial and palatal aspects (eg, VIP Light, Bisco, Inc, Schaumburg, IL; Optilux 501, Kerr/Sybron, Orange, CA) (Figures 8 and 9).

In order to avoid formation of microcracks in the thin facial enamel layer, the authors combined pulse-curing and progressive-curing techniques for placement of wedge-shaped composite increments.¹⁴ These techniques were adopted in an attempt to reduce polymerization shrinkage and decrease stress at the enamel-composite interface. A microhybrid resin (eg, Vitalescence, Ultradent Products, South Jordan, UT; Esthet-X, Dentsply/Caulk, Milford, DE; Point 4, Kerr/Sybron, Orange, CA) was selected to restore this tooth via the natural layering technique.¹⁵ Stratification was initiated using 1-mm to 1.5-mm, triangular-shaped, apico-occlusal placed layers of shaded composite (Figures 10 and 11). This uncured composite was condensed and sculpted against the palatal enamel shell; each increment was pulse-cured for 3 seconds at 200 mW/cm² to avoid microcrack formation and to reinforce the weak enamel wall. Final polymerization of the composite palatal wall was subsequently completed at 300 mW/cm² for 40 seconds. The pulp chamber was then stratified using 1-mm to 1.5-mm wedge-shaped increments that were strategically placed to a single surface in order to decrease the ratio between bonded and unbonded surfaces (ie, C-factor ratio). Increasing this ratio would have resulted in increased stress from polymerization.¹⁶ The dentin portion of the pulp chamber was filled using higher chroma shades in the most cervical portion of the preparation (A5, A4) and lower chromas (A3.5, A3) in the middle third according to the stratified layering technique (Figure 12).¹⁷ Each dentin increment was cured using a progressive curing technique (40 seconds at 300 mW/cm²) instead of

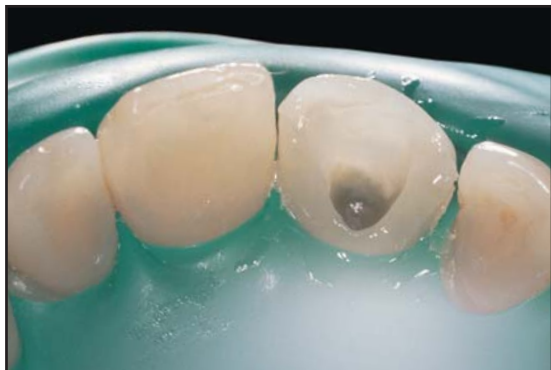

Figure 8. An ethanol-based adhesive system was placed on the prepared tooth surfaces and air thinned.

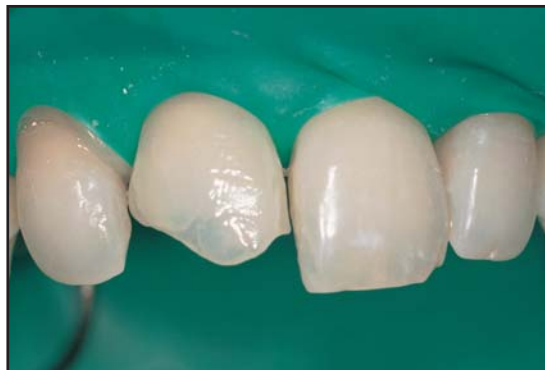

Figure 9. The facial aspect of the restoration was light cured for 20 seconds.

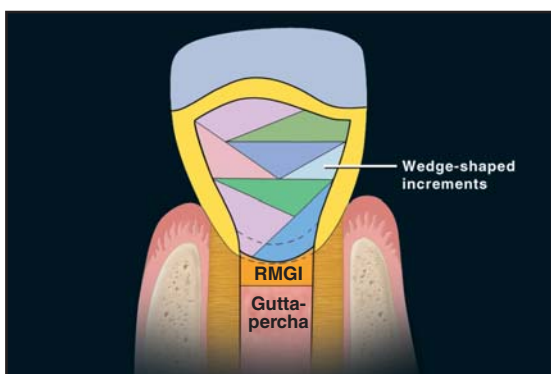


Figure 10. Schematic representation of wedge-shaped increments used to reinforce the weak facial enamel frame.

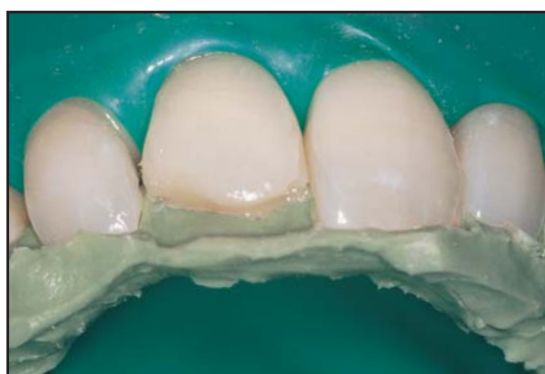

Figure 11. Wedge-shaped increments of composite were applied to the palatal enamel frame, and the pulp chamber was filled with composite resin.

a conventional continuous irradiation mode of 20 seconds at 600 mW/cm^2 . Once stratification of the pulp chamber was completed, the silicone template was placed to reconstruct the remaining tooth structure and Teflon strips were used as matrix in the adjacent teeth. An opalescent-shaded enamel was placed against this template in order to reproduce the palatal and proximal anatomy. Fluorescent dentin shades (ie, A1 and A2) were used to reconstruct the remaining dentin layer using the aforementioned placement and progressive curing techniques. An A1 shade was sculpted to mimic the mamelon effect of natural teeth. Dentin shades were not placed in the most incisal portion of the tooth to allow translucent enamel shades to be placed between mamelons and reproduce the translucency of natural teeth. An enamel layer of opalescent shade was applied to the final contour on the proximal and facial enamel (Figure 13). This final layer was pulse-cured for 3 seconds at 200 mW/cm^2 . The materials were allowed to set for 3 minutes to facilitate stress relief prior to final polymerization (30 seconds at 600 mW/cm^2).

Opalescent and translucent enamel shades were then used to reshape the distal and mesial incisal corners

of tooth #9. A pulse-curing technique was used to avoid the formation of enamel microcracks and limit their depth in the mesial aspect. The rubber dam was removed, occlusion was verified, and the restoration was polished (eg, Jiffy Composite Polishing System, Ultradent Products, South Jordan, UT; Contouring and Polishing Discs, 3M ESPE, St. Paul, MN) (Figure 14).

The tooth shade and anatomy were noticeably altered following completion of the bleaching and composite buildup treatments. Minimal composite modifications on tooth #9 allowed improved symmetry and harmony between the central incisors. A reduced brightness of the composite resin was observed 2 years post-operatively. While this phenomenon may have been related to composite wear due to incorrect use of toothbrush and/or use of abrasive toothpaste (Figure 15), this effect was easily reduced by polishing using extra-fine discs and points embedded with polishing pastes.¹⁸

Discussion

This case represents an example of resin composite longevity in the anterior region. Although minimal residual tooth structure and severe discoloration of the

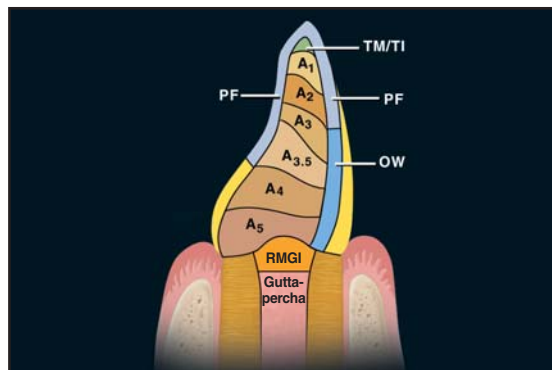


Figure 12. Illustration demonstrates aesthetic dentin and enamel composite resin stratification.

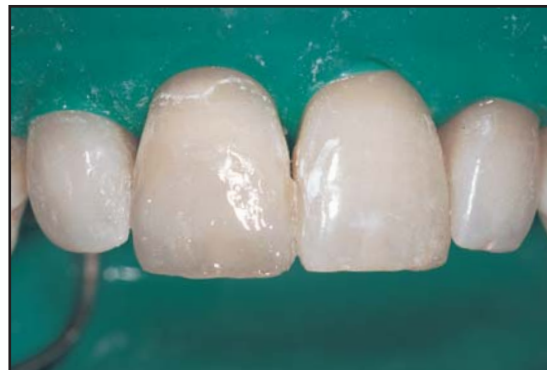

Figure 13. The enamel palatal and proximal layers were stratified using an opalesscent shade, and A2 and A1 dentin shades were applied.

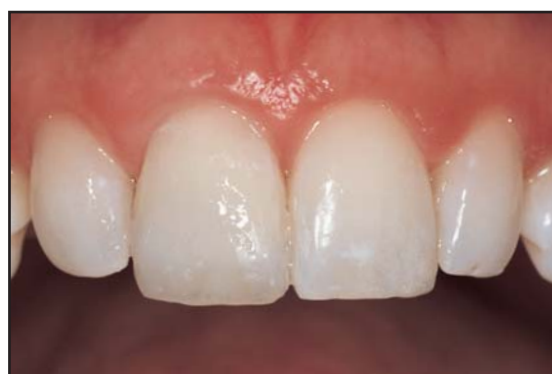

Figure 14. The anatomy and shape of tooth #9(21) was corrected and the rubber dam was removed.

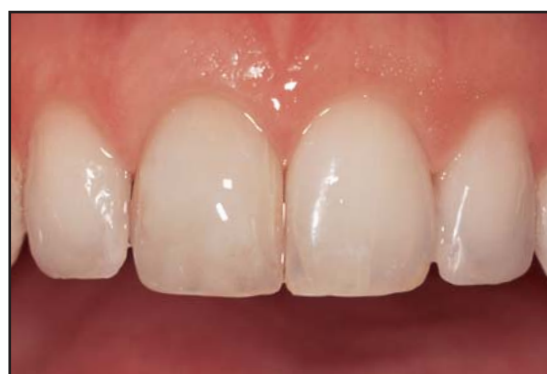

Figure 15. Postoperative appearance 2 years following restoration demonstrates a dramatic aesthetic improvement following tooth whitening and restoration.

endodontically treated tooth were evident, the shade match was maintained 2 years postoperatively. No marginal discoloration, recurrent decay, chipping, or composite clefts were detected following 2 years of clinical service. Although the observation was limited to this recall period and only one case report was considered, the clinical performance of the microhybrid composite resin was more than acceptable.

This result may also be related to the curing or composite placement techniques utilized. Composite polymerization shrinkage can also be controlled by the rate of polymerization and the composite placement technique. It was demonstrated that a pulse-curing technique was able to reduce enamel microcracks that may be particularly relevant when enamel is not supported by the underlying dentin as in the aforementioned case.¹⁹ Lower light intensity and increased curing periods have demonstrated improved marginal adaptation and composite physical properties.^{20,21} A progressive curing technique may, therefore, be critical in reducing stress at the cavosurface margins during polymerization of dentin increments. In order to decrease the C-factor ratio, it is critical to place strategic layers of wedge-shaped composite increments to a

single surface, or to the minimal number of bonded surfaces, without contacting opposing cavity walls.⁷

The literature has reported concerns regarding the use of adhesive techniques to restore endodontically treated teeth.²² While sodium hypochlorite (NaOCl) and hydrogen peroxide (H₂O₂) have been identified as common irrigants used during endodontic therapy, NaOCl has been shown to damage organic (ie, collagen), as well as inorganic, components (ie, magnesium and carbonate ions) of dentin. Additional research is required to explore the changes endured by endodontic treatment during adhesive protocols.^{23,24}

Conversely, the effects of H₂O₂ on tooth structure may not be permanent. The effect of peroxides on bleached tooth structure has been studied more extensively, and changes in the ultramorphology of enamel, dentin, and cementum following exposure to hydrogen peroxide or carbamide peroxide have been described. Alteration of the organic and inorganic component ratios and increased dental solubility of cementum and dentin more than enamel are the most common side effects reported.²⁵ Oxygen inhibition during polymerization of adhesives and resin composites thus increases

microleakage and reduces bond strength. It is, however, well known that these effects are reversible and short lived; delaying bonding procedure for up to two weeks can restore bond strength and reduce microleakage, and the buffering effect of saliva, and the fluoride content in the bleaching solution may further reduce these ultra-morphological changes.

The aforementioned composite resin buildup was performed without the use of a quartz fiber or a carbon fiber post. Although the scarce remaining tooth structure could have suggested a similar procedure, use of a cemented post may not reinforce endodontically treated teeth.^{26,27} In fact, such a post might have further weakened the tooth structure, particularly in the coronal cervical third. The remaining tooth structure surrounding the root of tooth #8 (ferrule) would have been less than 1 mm following tooth preparation, thus increasing the risk of post debonding.^{28,29} Posts can facilitate core retention and improve distribution of functional loads throughout the root. In the aforementioned case presentation, the residual facial enamel shell was considered the optimal means for obtaining composite retention. Occlusion was balanced with acceptable canine guidance and no signs of bruxism or parafunction.

The composite buildup presented in this article facilitates development of aesthetic restorations by eliminating interference caused by post cementation. In the event that the endodontically treated tooth requires retreatment, the procedure is more efficient and less complicated if a post is not used. Conversely, if a post is used, residual resin cement from the previous bonded post can interfere with the cementation of the new post following post removal and retreatment, thus increasing the risk of debonding. The technique presented in this article may be considered the treatment of choice for teeth with large periapical lesions and a doubtful prognosis even following endodontic therapy.

Conclusion

The clinical case presented may be considered challenging, and further in vitro and clinical studies are required. Continuous improvement of adhesive and composite systems, along with the use of curing and placement techniques that can better control polymerization shrinkage may, however, justify the increased use of direct composite resin for severely damaged teeth. Incorporation of in-office and at-home whitening will further increase patient satisfaction following restorative procedures. As contemporary modes of treatment continue to evolve, the clinical armamentarium will evolve, providing more predictable, aesthetic, and functional options for direct treatment protocols.

Acknowledgment

The authors declare no financial interest in any of the products cited herein.

References

1. Haywood VB, Heymann HO. Nightguard vital bleaching. *Quint Int* 1989;20(3):173-176.
2. Jordan RE, Suzuki M. Posterior composite restorations. Where and how they work best. *J Am Dent Assoc* 1991;122(12):30-37.
3. Christensen GJ. Amalgam vs. composite resin: 1998. *J Am Dent Assoc* 1998;129(12):1757-1759.
4. Hickel R, Manhart J, Garcia-Godoy F. Clinical results and new developments of direct posterior restorations. *Am J Dent* 2000;13(Spec No):41D-54D.
5. Van Meerbeek B, Peumans M, Gladys S, et al. Three-year clinical effectiveness of four total-etch dental adhesive systems in cervical lesions. *Quint Int* 1996;27(11):775-784.
6. Swift EJ Jr, Perdigão J, Wilder AD Jr, et al. Clinical evaluation of two one-bottle dentin adhesives at three years. *J Am Dent Assoc* 2001;132(8):1117-1123.
7. Liebenberg WH. Assuring restorative integrity in extensive posterior resin composite restorations: Pushing the envelope. *Quint Int* 2000;31(3):153-164.
8. Wendt SL Jr, Harris BM, Hunt TE. Resistance to cusp fracture in endodontically treated teeth. *Dent Mater* 1987;3(5):232-235.
9. Hernandez R, Bader S, Boston D, Trope M. Resistance to fracture of endodontically treated premolars restored with new generation dentine bonding systems. *Int Endod J* 1994;27(6):281-284.
10. Ausiello P, De Gee AJ, Rengo S, Davidson CL. Fracture resistance of endodontically-treated premolars adhesively restored. *Am J Dent* 1997;10(5):237-241.
11. Degrange M. Nonvital teeth: A list of questions. *J Adhes Dent* 2001;3(4):291.
12. Goldstein RE, Garber DA. Complete dental bleaching. Carol Stream, IL: Quintessence Publishing, 1995.
13. Settembrini L, Gultz J, Kaim J, Scherer WW. A technique for bleaching nonvital teeth: Inside/outside bleaching. *J Am Dent Assoc* 1997;128(9):1283-1284.
14. Deliperi S, Bardwell DN. An alternative method to reduce polymerization shrinkage in direct posterior composite restorations. *JADA* 2002;133:1387-1398.
15. Dietschi D. Layering concepts in anterior composite restorations. *J Adhes Dent* 2001;3(1):71-80.
16. Feilzer AJ, De Gee AJ, Davidson CL. Setting stress in composite resin in relation to configuration of the restoration. *J Dent Res* 1987;66(11):1636-1639.
17. Vanini L. Light and color in anterior composite restorations. *Pract Periodont Aesthet Dent* 1996;8(7):673-682.
18. Goldstein GR, Lerner T. The effect of toothbrushing on a hybrid composite resin. *J Prosthet Dent* 1991;66(4):498-500.
19. Kanca J 3rd, Suh BI. Pulse activation: Reducing resin-based composite contraction stresses at the enamel cavosurface margins. *Am J Dent* 1999;12(3):107-112.
20. Miyazaki M, Oshida Y, Moore BK, Onose H. Effect of light exposure on fracture toughness and flexural strength of light-cured composites. *Dent Mater* 1996;12(6):328-332.
21. Sakaguchi RL, Berge HX. Reduced light energy density decreases post-gel contraction while maintaining degree of conversion in composites. *J Dent* 1998;26(8):695-700.
22. Nikaido T, Takano Y, Sasafuchi Y, et al. Bond strengths to endodontically-treated teeth. *Am J Dent* 1999;12(4):177-180.
23. Inaba D, Ruben J, Takagi O, Arends J. Effect of sodium hypochlorite treatment on remineralization of human dentin in vitro. *Caries Res* 1996;30(3):218-224.
24. Perdigão J, Lopes M, Geraldini S, et al. Effect of a sodium hypochlorite gel on dentin bonding. *Dent Mater* 2000;16(5):311-323.
25. Perdigão J, Francci C, Swift EJ Jr, et al. Ultra-morphological study of the interaction of dental adhesives with carbamide peroxide-bleached enamel. *Am J Dent* 1998;11(6):291-301.
26. Sorensen JA, Engelman MJ. Effect of post adaptation on fracture resistance of endodontically treated teeth. *J Prosthet Dent* 1990;64(4):419-424.
27. Cohen BI, Pagnillo MK, Condos S, Deutch AS. Four different core materials measured for fracture strength in combination with five different designs of endodontic posts. *J Prosthet Dent* 1996;76(5):487-495.
28. Trabert KC, Caputo AA, Abou-Rass M. Tooth fracture — A comparison of endodontic and restorative treatments. *J Endod* 1978;4(11):341-345.
29. Ferrari M, Vichi A, Mannocci F, Mason PN. Retrospective study of the clinical performance of fiber posts. *Am J Dent* 2000;13(Spec No):9B-13B.

CONTINUING EDUCATION (CE) EXERCISE No. 8



To submit your CE Exercise answers, please use the answer sheet found within the CE Editorial Section of this issue and complete as follows: 1) Identify the article; 2) Place an X in the appropriate box for each question of each exercise; 3) Clip answer sheet from the page and mail it to the CE Department at Montage Media Corporation. For further instructions, please refer to the CE Editorial Section.

The 10 multiple-choice questions for this Continuing Education (CE) exercise are based on the article "Reconstruction of severely damaged endodontically treated and bleached teeth using a microhybrid composite resin: Two-year case report" by Simone Deliperi, DDS, David N. Bardwell, DMD, MS, and M. Debora Congiu, DDS. This article is on Pages 221-226.

1. What is the main disadvantage of post application in anterior teeth?

- a. The final aesthetic result is compromised.
- b. The post can interfere with a correct stratification technique.
- c. The post can debond.
- d. The remaining tooth structure is weakened.

2. Which of the following curing techniques was used to polymerize the enamel facial portion of the restoration?

- a. A pulse-curing technique.
- b. A soft start polymerization.
- c. A conventional continuous irradiation.
- d. None of the above.

3. Which of the following composite placement technique was used to build up the composite restoration?

- a. A horizontal technique.
- b. An oblique technique.
- c. A successive cusp buildup technique.
- d. A combination of an oblique and successive cusp buildup technique.

4. Which of the following curing techniques was used to polymerize the dentin portion of the restoration?

- a. A conventional continuous irradiation.
- b. A pulse-curing technique.
- c. A progressive-curing technique.
- d. A soft start polymerization.

5. What is the effect of NaOCl on the interaction of bonding agents with tooth structure?

- a. Increased bond strength of composite resin to tooth structure.
- b. Damage to organic, as well as inorganic, components of dentin and change in the surface tension of the substrate.
- c. Helps to reduce microleakage.
- d. Increased thickness of hybrid layer.

6. What resin material was used as a replacement for dentin and enamel?

- a. A flowable and a microhybrid composite.
- b. A flowable composite.
- c. A microhybrid composite.
- d. A flowable and a packable composite.

7. What is the exact meaning of "inside/outside bleaching technique?"

- a. The application of a bleaching material both on the pulp chamber and facial surface in a bleaching tray.
- b. The application of the bleaching material only on the pulp chamber.
- c. The application of the bleaching material only on the dental tissues but not on the old composite resin.
- d. The combination of in-office and at-home bleaching materials.

8. What is the correct thickness of each layer of resin-based composite to be polymerized in the incremental technique?

- a. 2 to 3 mm.
- b. Less than 2 mm.
- c. 3 to 4 mm.
- d. More than 4 mm.

9. What is the clinical indication for the use of microhybrid composite?

- a. Class III and V.
- b. Class I and II.
- c. Composite veneer.
- d. All of the above.

10. Which of the following types of restorative material was used as a barrier to avoid peroxide leakage at the CEJ?

- a. Glass ionomer.
- b. Resin-modified glass ionomer.
- c. Resin-based composite.
- d. Compomer.