

# Two-Year Clinical Evaluation of Nonvital Tooth Whitening and Resin Composite Restorations

SIMONE DELIPERI, DDS\*

DAVID N. BARDWELL, DDS, MS<sup>†</sup>

## ABSTRACT

**Background:** Adhesive systems, resin composites, and light curing systems underwent continuous improvement in the past decade. The number of patients asking for ultraconservative treatments is increasing; clinicians are starting to reevaluate the dogma of traditional restorative dentistry and look for alternative methods to build up severely destroyed teeth.

**Purpose:** The purpose of this study was to evaluate the efficacy of nonvital tooth whitening and the clinical performance of direct composite restorations used to reconstruct extensive restorations on endodontically bleached teeth.

**Materials and Methods:** Twenty-one patients 18 years or older were included in this clinical trial, and 26 endodontically treated and bleached maxillary and mandibular teeth were restored using a microhybrid resin composite. Patients with severe internal (tetracycline stains) and external discoloration (fluorosis), smokers, and pregnant and nursing women were excluded from the study. Only patients with A3 or darker shades were included. Teeth having endodontic access opening only to be restored were excluded; conversely, teeth having a combination of endodontic access and Class III/IV cavities were included in the study. A Vita shade guide (Vita Zahnfabrik, Bad Säckingen, Germany) arranged by value order was used to record the shade for each patient. Temporary or existing restorations were removed, along with a 1 mm gutta-percha below the cemento-enamel junction (CEJ), and a resin-modified glass ionomer barrier was placed at the CEJ. Bleaching treatment was performed using a combination of in-office (OpalescenceXtra, Ultradent Products, South Jordan, UT, USA) and at-home (Opalescence 10% PF, Ultradent Products) applications. Two weeks after completion of the bleaching, the teeth were restored using a combination of PQ1 adhesive system and Vit-l-escence microhybrid resin composite (Ultradent Products). Wedge-shaped increments were placed and cured using the VIP Light (Bisco, Inc Schaumburg, IL, USA) through a combination of pulse and progressive curing techniques.

**Results:** All but one restoration were evaluated by two independent evaluators every 6 months during a 2-year period using modified US Public Health Service criteria. No restoration failed and “alpha” scores were recorded for all parameters but color stability, which was scored “bravo.” Analysis of variance showed a significant shade change between baseline (mean = 14.4 ± 1.9) versus 2 weeks (mean = 1.6 ± 0.7) and 2 years (mean = 2.8 ± 1.7) ( $p < .0001$ ). Although a significant shade change was observed between 2 weeks and the 2-year follow-up ( $p = .008$ ), no significant difference was reported between the baseline and 2 weeks (12.9 ± 2) versus baseline and 2 years (11.9 ± 2.3).

\*Visiting instructor and research associate, Tufts University School of Dental Medicine, Boston, MA, USA, and private practice, Cagliari, Italy

<sup>†</sup>Associate clinical professor of Restorative Dentistry and former director Postgraduate Esthetic Dentistry, Tufts University School of Dental Medicine, Boston, MA, USA

**Conclusions:** Significant tooth lightening was reported after the completion of whitening therapy on devitalized teeth; shade rebound was reported in less than 50% of the treated teeth and was limited to a maximum of four shades. A microhybrid resin composite demonstrated excellent clinical performance in the restoration of all endodontically treated and bleached teeth after a 2-year evaluation period.

#### CLINICAL SIGNIFICANCE

Nonvital tooth whitening is responsible for a significant change in color of endodontically stained teeth. Successful nonvital tooth-whitening therapy allows for conservative tooth preparation, preserving and reinforcing sound tooth structure. The proper use of modern adhesive systems along with resin composite restorations precludes the use of more extensive restorative treatment, delaying expensive crown and bridge procedures.

(*J Esthet Restor Dent* 17:369–379, 2005)

Over the past decade, the restoration of endodontically treated teeth has been associated with a combination of prefabricated or custom-made metallic posts and cores and full crowns<sup>1</sup>; a considerable amount of coronal and radicular tooth structure was sacrificed, increasing the risk of root perforation and fracture.<sup>2,3</sup> Moreover, patient acceptance is costly and time consuming for the patient.<sup>4</sup>

Lately, there has been an expansion in cosmetic dentistry owing to the introduction of nightguard vital bleaching,<sup>5,6</sup> the continued development of total-etch adhesive systems,<sup>7–10</sup> and the improvement of resin-bonded composite (RBC) physical and mechanical properties.<sup>11,12</sup> Nonvital teeth have become primary benefactors of these new developments. The combination of tooth whitening and modern adhesive dentistry has allowed clinicians to preserve remaining sound tooth structure.

This is considered paramount for a successful outcome. Some laboratory studies have demonstrated that modern adhesive systems in combination with direct resin composites can adequately reinforce remaining tooth structure.<sup>13,14</sup> These findings have encouraged clinicians to restore nonvital teeth by replacing only missing tooth structure in a minimally invasive manner. Patient demands for esthetic restorations, coupled with their desire to save remaining sound tooth structure, are pushing dentists to stretch present-day clinical indications for direct RBC restorations.<sup>15,16</sup> This situation may be further influenced by a patient's inability to afford the ideal indirect restoration in large posterior or anterior applications.

As a consequence, clinical indications for anterior and posterior RBC restorations have progressively expanded; practitioners are looking for new materials and techniques to further enhance the clinical performance of direct RBCs

when placed in severely destroyed vital or nonvital teeth.<sup>15,16</sup> However, the mechanism of dentin bonding to endodontically treated teeth, and the longevity of this bond, has yet to be explored. Similarly, research has not provided long-term data regarding the clinical performance of modern adhesive systems with previously bleached teeth.

Conversely, it has become clear in literature reviews that metal posts do not strengthen endodontically treated teeth. Their use is justified only for retention of the coronal restoration.<sup>17,18</sup> Post preparation may be responsible for the destruction of sound tooth structure, and tooth perforation can occur during instrumentation. Teeth with remaining coronal structure may not require the cementation of a post if correct adhesive techniques are used.<sup>19,20</sup>

The purpose of this study was to evaluate the clinical performance of

direct composite restorations when a microhybrid resin composite is used to reconstruct previous endodontically treated and bleached anterior teeth. The hypothesis of our study was three-fold; we hypothesized that there would be (1) tooth color modification greater than five shades on the Vita shade guide (Vita Zahnfabrik, Bad Säckingen, Germany) arranged in value order, (2) rebound not greater than two shades at each annual recall, and (3) a 100% resin composite retention rate at the 6-month recall.

#### MATERIALS AND METHODS

Twenty-one patients 18 years or older were included in this clinical trial to bleach and restore endodontically treated maxillary and mandibular anterior teeth. Patients with severe internal and external discoloration (tetracycline stains, fluorosis), smokers, and pregnant and nursing women were excluded from the study. Teeth having previous bleaching treatments and with a complete loss of clinical crown were also excluded, were teeth having endodontic access opening only to be restored. Informed consent was obtained prior to the commencement of the study.

Only patients having had pulpless anterior teeth endodontically treated at least 2 years prior with A3 or darker shades were included in the study. Only teeth having a combination of endodontic access and Class III/IV cavities were

included in the study. Sixteen of 25 teeth had a combination of proximal surface and incisal edge (Class III plus Class IV) restorations with endodontic access; the remaining teeth had at least a Class III restoration, along with endodontic access, to be restored. All subjects received a dental prophylaxis 2 weeks prior to the start of bleaching.

A Vita shade guide arranged by value order (lightest to darkest) was used to record the shade for each patient.

An alginate impression of the maxillary or mandibular arch was taken, poured with dental stone, and the resultant casts were trimmed and prepared for a custom stent; a light-cured resin blockout material (LC Block-out Resin, Ultradent Products, South Jordan, UT, USA) was placed on the facial aspect 1 mm from the gingival area. Trays were fabricated with a 0.089 cm (0.035 inch) thick, 12.5 × 12.5 cm (5 × 5 inch) soft tray material used in a heat/vacuum tray-forming machine. Each tray was properly trimmed to perfectly fit its model before it was tried in the patient. Patients were instructed on the correct care and use of the trays. Gutta-percha was removed 1 mm below the crown prior to whitening, and a barrier was placed at the cemento-enamel junction using a resin-modified glass ionomer (Vitrebond, 3M ESPE, St. Paul, MN, USA), which was light cured for 40 seconds.

Prior to the start of in-office bleaching, teeth were pumiced and gingival tissue isolation was performed using a light-cured resin dam (OpalDam, Ultradent Products). A 35% hydrogen peroxide gel (OpalescenceXtra, Ultradent Products) was applied into the pulp chamber and on the facial enamel for 30 minutes. The in-office bleaching treatment was maintained and reinforced using a 10% carbamide peroxide at-home bleaching agent (Opalescence 10% PF, Ultradent Products) according to the inside/outside bleaching technique.<sup>21</sup> Shades were recorded 14 days after the completion of the home-bleaching treatment and 1 week after the restoration was completed. The endodontic access was not sealed during the tooth-whitening procedures and the 2-week waiting period following the completion of nonvital bleaching.

A rubber dam was placed and cavity preparation was completed, rounding sharp angles with no. 2 and 4 burs (Shofu Dental Corporation, San Marcos, CA, USA) and placing a 1 mm bevel into the facial surface with a no. 7104 bur (Shofu Dental Corporation). The cavity was disinfected for 60 seconds using a 2% chlorhexidine antibacterial solution (Consepsis, Ultradent Products). The tooth was etched for 15 seconds using a 35% phosphoric acid (UltraEtch, Ultradent Products); the etchant was removed and the cavity was water sprayed for 30 seconds, being careful to maintain a moist surface. A fifth-

generation, 40% filled, ethanol-based adhesive system (PQ1, Ultra-dent Products) was placed in the preparation, gently air thinned until the milky appearance disappeared, and light cured for 20 seconds on the facial and palatal aspects using a quartz-tungsten-halogen light (VIP Light, Bisco Inc., Schaumburg, IL, USA). Vit-l-escence microhybrid resin composite (Ultradent Products, South Jordan, UT) was used to restore the teeth. Stratification was started using OW Vit-l-escence shade placed in 1 to 1.5 mm, triangular-shaped (wedge-shaped), apico-occlusal layers. This uncured composite was condensed and sculpted against the palatal enamel wall, and each increment was pulse cured for 3 seconds at 200 mW/cm<sup>2</sup> to avoid microcrack formation.<sup>22</sup>

Once the waiting period of 3 minutes was satisfied, the polymerization of composite increments was completed using a higher intensity and longer curing time (Table 1). At this point, stratification of the pulp chamber was started using 1 to 1.5 mm dentin wedge-shaped increments, which were strategically

placed to a single surface to decrease the C-factor ratio.<sup>15,22</sup> Each dentin increment was cured using a progressive curing technique (40 s at 300 mW/cm<sup>2</sup> instead of a conventional continuous irradiation mode of 20 s at 600 mW/cm<sup>2</sup>). To compensate for the increased polymerization time, two different increments were placed in the opposite cavity walls without contacting each other. An enamel layer of Pearl Frost or Pearl Neutral was applied to the final contour on the proximal and facial enamel. This final layer was pulse cured for 3 seconds at 200 mW/cm<sup>2</sup>. A waiting time of 3 minutes was allowed for stress relief before a final polymerization at a higher intensity (30 seconds at 600 mW/cm<sup>2</sup>) was started.

Three expert investigators were involved: the first investigator bleached and restored the teeth; the second and third investigators evaluated the restorations at 6-month recalls. Restorations were evaluated by two investigators precalibrated at 85% reliability. Disagreement was resolved with consensus opinions.

Figures 1 to 4 show the typical case, with preoperative and postoperative views, the radiographic evaluation, and the 2-year recall of endodontically treated teeth after completion of bleaching and restorative procedures.

## RESULTS

All but one restoration was evaluated every 6 months during a 2-year period using modified US Public Health Service criteria by two independent evaluators. As these criteria were first used to score bleached teeth, a new parameter was introduced to evaluate tooth color modification over the 2-year follow-up period (tooth color stability; Table 2). Pictures were taken at each recall. No restoration failed, and “alpha” scores were recorded for all parameters except color stability, which was scored “bravo” (Table 3 and Figure 5).

Statistical analysis was performed using analysis of variance (ANOVA); post hoc comparison (Dunnett’s T3 method) was adopted to correct for type I errors, and an

**TABLE 1. RECOMMENDED PHOTOCURING TIMES AND INTENSITIES FOR ENAMEL AND DENTIN BUILDUP IN SEVERELY DAMAGED ENDODONTICALLY BLEACHED TEETH.**

Buildup	Composite Shade (Vitaescence)	Polymerization Technique	Intensity (mW/cm <sup>2</sup> )	Time (s)
Palatal enamel	OW	Pulse	200	3
		Progressive curing	300	40
Dentin	A5-A4-A3.5-A3-A2-A1	Progressive curing	300	40
Facial enamel	PF-TM-TF-TI	Pulse	200	3
		Final curing	600	10 (incisal), 10 (facial), 10 (palatal)

independent sample *t*-test was also used when appropriate. Analysis was performed using the Statistical Package for Social Science software (SPSS Inc., Chicago, IL, USA). ANOVA showed a significant tooth shade change between baseline (mean =  $14.4 \pm 1.9$ ) versus 2 weeks (mean  $1.6 \pm 0.7$ ) and 2 years (mean

$2.8 \pm 1.7$ ) ( $p < .0001$ ). A summary of the mean tooth shade change is reported in Table 4.

Post hoc tests showed a significant shade change between baseline and 2 weeks (mean difference 12.9,  $p < .0001$ ) and between baseline and 2 years (mean difference 11.7,

$p < .0001$ ). Although the mean shade change between 2 weeks and 2 years was just 1.2, the difference was statistically significant ( $p = .008$ ). However, there was no significant difference between baseline and 2 weeks ( $12.9 \pm 2$ ) versus baseline and 2 years ( $11.9 \pm 2.3$ ,  $t_{df=48} = 1.96$ ,  $p > .05$ ).

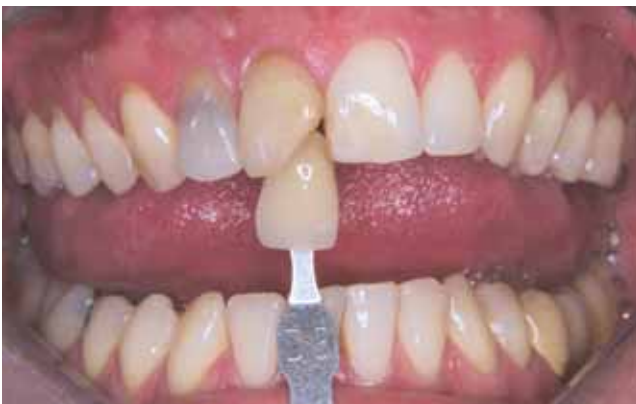

Figure 1. Preoperative retracted view of discolored, devital upper right central and lateral incisors in need of restoration. The upper vital left central incisor presented an existing resin composite restoration. The upper right central was fractured, devitalized, and restored with resin composite 8 years earlier; restoration debonding and discoloration is evident, as are horizontal and vertical enamel cracks.

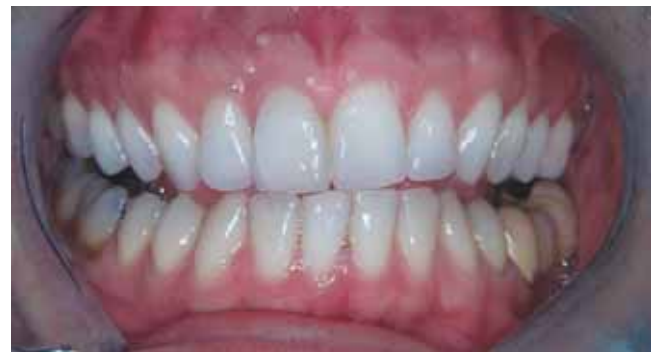

Figure 2. A significant change in shade was observed on both upper right central and lateral incisors once tooth whitening and the direct resin composite restorations were completed. The anatomy and shape of the upper vital left central incisor was also corrected (final result at the 2-week recall). Enamel cracks became more evident once the discoloration was removed on both the cervical third and distal incisal line angle of upper right central incisor. The cracks were related to trauma that occurred 8 years earlier.

Figure 3. Radiograph of the upper right central and lateral incisors following the restorative procedure.

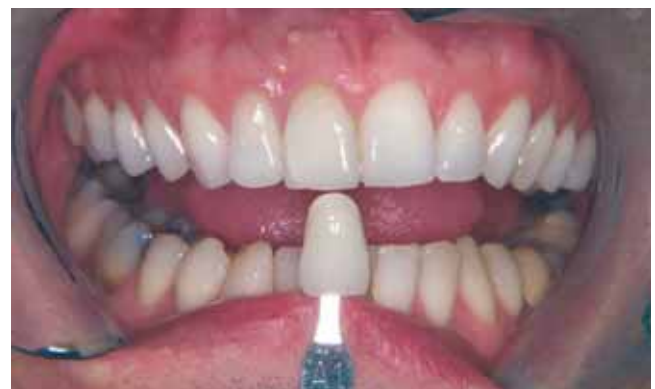
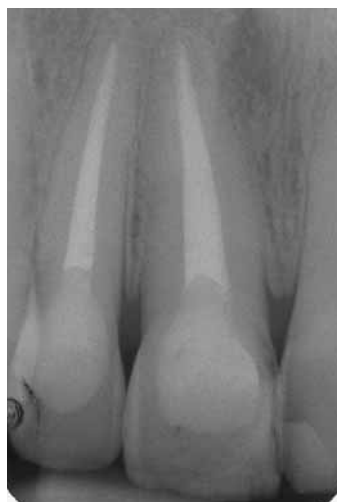
Figure 4. Postoperative appearance 2 years following the restoration demonstrates the maintenance of a good esthetic result on both devital and vital teeth. Enamel cracks did not show any further development.



TABLE 2. MODIFIED USPHS CRITERIA USED FOR DIRECT CLINICAL EVALUATION OF THE RESTORATIONS.

Score	Alpha	Bravo	Charlie	Delta
Tooth color stability	No change	Change of color comparing to baseline condition (up to 4 shades)	Change of color comparing to baseline condition (up to 8 shades)	Change of color comparing to baseline condition (> 8 shades)
Surface texture	Sound	Rough	—	—
Anatomic form	Sound	Slight loss of material (chipping, clefts); superficial	Strong loss of material (chipping, clefts); profound	Total or partial loss of bulk
Marginal integrity (enamel)	Sound	Positive step, removable by finishing	Slight negative step not removable, localized	Strong negative step in major parts of the margin, not removable
Marginal discoloration (enamel)	None	Slight discoloration, removable by finishing	Discoloration, localized not removable	Strong discoloration in major parts of the margin not removable
Secondary caries	None	Caries present	—	—
Gingival inflammation	None	Slight	Moderate	Severe
Restoration color stability	No change	Change of color comparing to baseline condition	—	—

USPHS = US Public Health Service.

## DISCUSSION

Nonrestored devitalized teeth are structurally compromised and represent one of the greatest challenges for the clinician. Restoration of endodontically treated teeth has been associated with the use of posts. Various post materials and design have been introduced over the years.<sup>23,24</sup> Lately, tooth-colored fiber posts have been introduced and demonstrated advantages over conventional metal posts.<sup>25,26</sup> They are esthetic, bond to tooth structure, and have a modulus of elasticity similar to that of dentin; however, they still require dentin preparation to fit the canal space, thus further weakening residual tooth structure. Moreover, cementation of a post can interfere with correct resin composite stratification in the lingual access creating a nones-

thetic restoration; in the event that the endodontically treated tooth needs re-treatment, the procedure can be hailed as faster and less complicated. Conversely, if a post is used, once removal and re-treatment is completed, residual resin cement can interfere with the adhesion of the new post, increasing risk of debonding. The motivation to protect the remaining sound tooth structure using the properties of modern adhesive systems has encouraged clinicians to reevaluate traditional restorative dogma. Alternate restorative methods for devitalized teeth have been embraced.<sup>15,27,28</sup>

Although the observation time is limited to only 2 years, the results of this clinical study are encouraging. Marginal integrity, anatomic

form, and texture were preserved over a 2-year follow-up period. No marginal discoloration, recurrent decay, chipping, or composite clefts were detected. Interestingly enough, this result supported the premise of direct resin buildups for severely destroyed nonvital and bleached teeth. Sixteen of 25 teeth had a combination of Class IV and III restorations with endodontic access; the remaining teeth had at least a Class III restoration along with endodontic access to be restored. One may argue that the sample size was limited, but the inability to select patients with such a narrow inclusion criteria made recruitment and selection difficult.

No previous study has followed up the clinical performance of direct

**TABLE 3. SHADE RECORDED AT BASELINE, 2 WEEKS AFTER COMPLETION OF THE RESTORATIONS, AND AT 2-YEAR FOLLOW-UP.**

Patient	Baseline	2 Weeks	2-Year Recall
		(No. of Shade Changes)	(No. of Shade Rebound)
1	A4	B1 (14)	B1 (0)
2	A4	B1 (14)	A1 (+1)
3	D3	B1 (9)	A1 (+1)
4	C4	A1 (14)	A2 (+2)
5	A3.5	A1 (10)	A1 (0)
6	C4	A1 (14)	A2 (+2)
7	C4	B1 (15)	B2 (+2)
	C4	B1 (15)	B1 (0)
8	C4	A1 (14)	A1 (0)
9	A3.5	A1 (10)	A1 (0)
	A3.5	A1 (10)	D2 (+2)
10	C4	B1 (15)	B1 (0)
	A4	B1 (14)	B1 (0)
	A4	B1 (14)	B1 (0)
11	D3	B1 (8)	A1 (+1)
	C3	B1 (13)	B1 (0)
12	C4	A1 (14)	A2 (+3)
13	C4	D2 (12)	C1 (+2)
14	A4	B1 (14)	B2 (+2)
15	A4	B1 (14)	B1 (0)
16	A3.5	A1 (10)	A2 (+3)
17	A4	A1 (13)	A1 (0)
18	C3	A1 (12)	A1 (0)
19	C4	B1 (15)	A2 (+4)
20	C4	A1 (14)	A2 (+3)

(Vita shade guide arranged in value order)

B1 A1 B2 D2 A2 C1 C2 D4 A3 D3 B3 A3.5 B4 C3 A4 C4  
(1) (2) (3) (4) (5) (6) (7) (8) (9) (10) (11) (12) (13) (14) (15) (16)

resin composite to reconstruct endodontically bleached teeth, although this technique has been widely reported in the literature.<sup>21,29,30</sup> Furthermore, comparison is impossible without this much-needed longitudinal data. Alpha scores were not recorded for “tooth color stability.” Shade

rebound was reported for 13 of 25 teeth. Statistical analysis reported a significant difference in shade change between 2 weeks and 2 years; one may argue that this is significant from a clinical point of view, keeping in mind that 17 of 25 teeth recorded a C4 or A4 shade at baseline. Moreover, 9 of these 13 teeth

had a shade change of just one or two shades. However, it is important to point out that all the teeth included in this study underwent endodontic treatment at least 2 years earlier. It would be interesting to find out whether the rebound trends are similar for recently discolored endodontically treated teeth. Even though no further bleaching treatment was administered, the lighter shade could easily have recovered with a 10% carbamide peroxide bleaching gel application.

Endodontically treated teeth can become fragile owing to the aggressive tooth preparation required for adequate endodontic treatment. In many cases, these teeth have significant loss of tooth structure owing to caries and/or trauma.

Pulpless teeth that undergo bleaching-restorative procedures may remain in a “hollow” condition for a period varying from a minimum of 4 weeks to a maximum of 8 weeks. The darkness of the tooth and its sensibility or reactivity to the bleaching process contribute to this latent period. The time required for the bleaching process to be completed plus the waiting time required for the shade to be stabilized can prolong restorability. The vulnerability of the tooth to fracture may increase during this phase until a final restoration is completed. When the tooth is in this hollow intermediate condition, patients must be instructed to avoid occlusal function.<sup>31</sup> For both

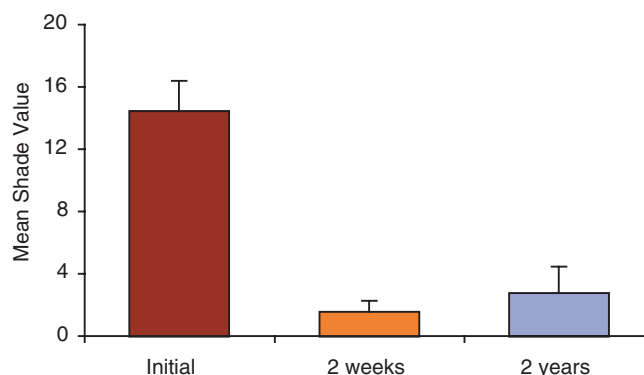


Figure 5. The graph shows the average tooth-color modification after completion of the bleaching treatment versus baseline, and the rebound trend at the 1- to 2-year recalls.

mechanical and esthetic reasons, it is advisable to retain intact enamel, even if it is only a shell.

Both vital and nonvital teeth may also be susceptible to weakening by improper restorative treatment resulting from polymerization stresses inherent with resin composites. It is critical to adopt an appropriate layering and curing technique.

To decrease the C-factor ratio, it is important to strategically place thin layers of wedge-shaped composite increments to a single surface. It is critical to ensure that the fewest number of bonded surfaces are contacting opposing cavity walls.<sup>16,22</sup> The curing technique can influence the clinical performance of direct

RBC restorations. Efforts were concentrated in delaying the gel point to give composite particles more time to flow into the direction of cavity walls, thus relieving stresses from polymerization shrinkage. Resin composite goes from a pregel state (early setting) to a postgel state (final setting) during polymerization; once the gel point is achieved, flow cannot occur because of the increased stiffness of the RBC.<sup>32-36</sup>

Previous research studies have demonstrated that a pulse curing technique can reduce stress development at the cavosurface margins, avoiding the formation of microcracks.<sup>22,37,38</sup> If a conventional continuous fast curing technique is

adopted, the bonding interface may remain intact but microcracks may develop just outside the cavosurface margins owing to these stresses.<sup>39,40</sup> Furthermore, lower light intensity and longer curing time has demonstrated an improvement in marginal adaptation while maintaining excellent physical properties of resin composite.<sup>41,42</sup> The progressive curing technique used to polymerize dentinal increments may be critical in transmitting lower stress at the cavosurface margins. Unfortunate as it may be, clinicians may prefer conventional curing methods to save time. This haste may increase the possibility of RBC postoperative sensitivity and reduced longevity.<sup>43,44</sup> This trend is also influenced by manufacturers resisting the use of alternative modes of polymerization in their light-curing systems. Clinicians cannot program their curing lights for mode polymerization and may be constrained by the curing intensity and time provided by manufacturers.

A previous publication has reported concerns regarding the use of adhesive techniques to restore endodontically treated teeth.<sup>45</sup> Sodium hypochlorite (NaOCl) and hydrogen peroxide (H<sub>2</sub>O<sub>2</sub>) are common irrigants used during endodontic therapy. NaOCl damages the organic components of dentin, mainly collagen,<sup>46</sup> as well as the inorganic components, mainly magnesium and carbonate ions.<sup>47</sup> Inaba and colleagues reported a recrystallization process of dentin after

TABLE 4. SUMMARY OF MEAN SHADE CHANGE AND PERCENT CHANGE FROM BASELINE.

Time	Mean ( $\pm$ SD)	Change from Baseline (%)
Baseline	14.4 ( $\pm$ 1.9)	—
2 wk after treatment	1.6 ( $\pm$ 0.7)	89%
2-years follow-up	2.8 ( $\pm$ 1.7)	81%



NaOCl treatment. Recrystallization was described to be related to the substitution of certain ions in the apatite crystals,<sup>46</sup> which may be responsible for changes in the surface tension of the substrate. Furthermore, dentin treatment with NaOCl resulted in a decreased bond strength even when tested in vital teeth.<sup>48,49</sup> This may suggest that the collagen layer may play a significant role in dentin adhesion. Its absence in endodontically treated teeth may influence the long-term clinical performance of RBCs. This drop in bond strength may be attributed to the oxidation inhibition. Furthermore, the deproteinizing effect of NaOCl can compound this problem; however, it may be reversed by the critical application of sodium ascorbate, a reducing agent.<sup>50</sup> Yiu and colleagues demonstrated a correlation between nanoleakage elimination and sodium ascorbate treatment on NaOCl-treated, acid-etched dentin.<sup>51</sup> It was also reported that residual NaOCl within the porosities of mineralized dentin was responsible for an incomplete resin polymerization. Liebenberg suggested the use of the enzyme catalase to eliminate the hydrogen peroxide residue.<sup>29</sup> However, the changes induced by endodontic treatment on hard dental tissues are poorly known at present, and further research is required to better explore this complex area of adhesive dentistry. The potential benefits of adhesive dentistry in this field have not been fully explored.<sup>52</sup>

Devitalized dentin is deprived of its odontoblastic process and collagen layer and may be modified by the use of conventional endodontic irrigants. A different hybrid layer may be created owing to the absence or reduced concentration of resin-impregnated collagen fibrils.

As oxygen is completely released from the tooth structure in a 2- to 3-week period,<sup>53</sup> a delay of restorative procedures may be recommended for teeth treated endodontically and bleached, in order to establish adequate bond strength.

#### CONCLUSION

Vit-I-escence microhybrid resin composite demonstrated excellent clinical performance in extensive restorations of endodontically bleached teeth after a 2-year evaluation period. Thirteen of 25 teeth evaluated underwent to a shade change, but 9 of these 13 teeth had a shade change of just one or two shades; this is the result of shade rebound. The lighter shade may be easily recovered with a 10% carbamide peroxide bleaching gel application.

#### DISCLOSURE

The authors do not have any financial interest in the companies whose materials are discussed in this article.

#### REFERENCES

1. Shillingburg HT, Hobo S, Whitsett LD, Jacobi R, Brackett SE. *Fundamentals of fixed prosthodontics*. Chicago, IL: Quintessence Publishing, 1997.
2. Fuss Z, Lustig J, Katz A, Tamse A. An evaluation of endodontically treated vertical root fractured teeth: impact of operative procedures. *J Endod* 2001; 27:46–48.
3. Sornkul E, Stannard JG. Strength of root before and after endodontic treatment and restoration. *J Endod* 1992; 18:440–443.
4. Stockton L, Lavelle CLB, Suzuki M. Are posts mandatory for the restoration of endodontically treated teeth? *Endod Dent Traumatol* 1998; 14:59–63.
5. Haywood VB, Heymann HO. Nightguard vital bleaching. *Quintessence Int* 1989; 20:173–176.
6. Haywood VB. History, safety, and effectiveness of current bleaching techniques and application of nightguard vital bleaching technique. *Quintessence Int* 1992; 23:471–488.
7. Swift EJ Jr, Perdigao J, Wilder AD, Heymann HO, Sturdevant JR, Bayne SC. Clinical evaluation of two one-bottle dentin adhesives at three years. *J Am Dent Assoc* 2001; 132:1117–1123.
8. Van Meerbeek B, Peumans M, Verschueren M, et al. Clinical status of ten dentin adhesive systems. *J Dent Res* 1994; 73:1690–1702.
9. Van Meerbeek B, Perdigao J, Lambrechts P, Vanherle G. The clinical performance of adhesives. *J Dent* 1998; 26:1–20.
10. Van Meerbeek B, Vargas M, Inoue S, et al. Adhesives and cements to promote preservation dentistry. *Oper Dent* 2001; 26 Suppl 6:119–144.
11. Hickel R, Manhart J, Garcia Godoy F. Clinical results and new developments of direct posterior restorations. *Am J Dent* 2000; 13:41D–54D.
12. Hickel R, Manhart J. Longevity of restorations in posterior teeth and reasons for failure. *J Adhes Dent* 2001; 3:45–64.
13. Ausiello P, De Gee AJ, Rengo S, Davidson CL. Fracture resistance of endodontically treated maxillary premolars, adhesively restored with various materials. *Am J Dent* 1997; 10:237–241.
14. Ausiello P, Davidson CL, Cascone P, De Gee AJ, Rengo S. Debonding of adhesively restored deep Class II restorations after functional loading. *Am J Dent* 1999; 12:84–88.

15. Deliperi S, Bardwell DN, Congiu MD. Clinical challenge: reconstruction of severely damaged endo/bleached teeth using a microhybrid composite resin. Two year case report. *Pract Proced Aesthet Dent* 2003; 15:221–226.
16. Liebenberg WH. Assuring restorative integrity in extensive posterior resin restorations: pushing the envelope. *Quintessence Int* 2000; 31:153–164.
17. Christensen GJ. Posts: necessary or unnecessary? *J Am Dent Assoc* 1996; 127:1522–1524.
18. Stockton L, Lavelle CLB, Suzuki M. Are posts mandatory for the restoration of endodontically treated teeth? *Endod Dent Traumatol* 1998; 14:59–63.
19. Göhring TN, Peters OA. Restorations of endodontically treated teeth without posts. *Am J Dent* 2003; 16:313–318.
20. Krejci I, Duc O, Dietschi D, de Campos E. Marginal adaptation, retention and fracture resistance of adhesive composite restorations on devital teeth with and without posts. *Oper Dent* 2003; 28:127–135.
21. Settembrini L, Gultz J, Kaim J, Scherer W. A technique for bleaching nonvital teeth: inside/outside bleaching. *J Am Dent Assoc* 1997; 128:1283–1284.
22. Deliperi S, Bardwell DN. An alternative method to reduce polymerization shrinkage in direct posterior composite restorations. *J Am Dent Assoc* 2002; 133:1387–1398.
23. Terry DA, Triolo PT, Swift EJ. Fabrication of direct fiber-reinforced posts: a structural design concept. *J Esthet Restor Dent* 2001; 13:228–240.
24. Heydecke G, Peters MC. The restoration of endodontically treated, single-rooted teeth with cast or direct posts and cores: a systematic review. *J Prosthet Dent* 2002; 87:380–386.
25. Ferrari M, Vichi A, Mannocci F, Mason PN. Retrospective study of the clinical performance of fiber posts. *Am J Dent* 2000; 13:9B–13B.
26. Qualtrough AJE, Mannocci F. Tooth-colored post systems: a review. *Oper Dent* 2003; 28:86–91.
27. Krejci I, Duc O, Dietschi D, de Campos E. Marginal adaptation, retention and fracture resistance of adhesive composite restorations on devital teeth with and without posts. *Oper Dent* 2003; 28:127–135.
28. Deliperi S, Bardwell DN, Coiana C. Reconstruction of devital teeth using direct fiber-reinforced composite resins: a case report. *J Adhes Dent*. (In press)
29. Liebenberg WH. Intracoronal lightening of discoloured pulpless teeth: a modified walking bleach technique. *Quintessence Int* 1997; 28:771–777.
30. Caughman FW, Frazier KB, Haywood VB. Carbamide peroxide whitening of nonvital single discolored teeth: case reports. *Quintessence Int* 1999; 30:155–161.
31. Baratieri LN, Ritter AV, Monteiro S, de Andrada MAC, Cardoso Viera LC. Non-vital tooth bleaching: guidelines for the clinician. *Quintessence Int* 1995; 26:597–608.
32. Uno S, Asmussen E. Marginal adaptation of a restorative resin polymerized at reduced rate. *Scand J Dent Res* 1991; 19:440–444.
33. Feilzer AJ, Dooren LH, De Gee AJ, Davidson CL. Influence of light intensity on polymerization shrinkage and integrity of restoration-cavity interface. *Eur J Oral Sci* 1995; 103:322–326.
34. Goracci G, Mori G, Casa de Martinis L. Curing light intensity and marginal leakage of resin composite restorations. *Quintessence Int* 1996; 27:355–362.
35. Mehl A, Hickel R, Kunzelman KH. Physical properties and gap formation of light cured composites with and without soft start polymerization. *J Dent* 1997; 25:321–330.
36. Deliperi S, Bardwell DN, Papathanasiou A. In vitro evaluation of composite microleakage using different methods of polymerization. *Am J Dent* 2003; 16:73A–76A.
37. Kanca J, Suh BI. Pulse activation: reducing resin-based composite contraction stresses at the cavosurface margins. *Am J Dent* 1999; 12:107–112.
38. Suh BI. Controlling and understanding the polymerization shrinkage-induced stresses in light cured composites. *Comp Contin Educ Dent* 1999; 20:S34–S41.
39. Han L, Okamoto A, Iwaku M. The effect of various clinical factors on marginal enamel microcracks produced around composite restoration. *Dent Mater* 1990; 6:26–37.
40. Prati C, Simpson M, Mitchem J, Tao L, Pashley DH. Relationship between bond strength and microleakage measured in the same Class I restorations. *Dent Mater* 1992; 8:37–41.
41. Miyazaki M, Yoshida Y, Moore K, Onose H. Effect of light exposure on fracture toughness and flexural strength of light-cured composites. *Dent Mater* 1996; 12:328–332.
42. Sakaguchi RL, Berge HX. Reduced light energy density decreases post gel contraction while maintaining degree of conversion. *J Dent* 1998; 26:695–700.
43. Christensen GJ. The curing light dilemma. *J Am Dent Assoc* 2002; 133:761–763.
44. Caughman WF, Rueggeberg FA. Shedding new light on composite polymerization. *Oper Dent* 2002; 27:636–638.
45. Nikaido T, Takano Y, Sasafuchi Y, Burrow MF, Tagami J. Bond strengths to endodontically-treated teeth. *Am J Dent* 1999; 12:177–180.
46. Inaba D, Ruben J, Takagi O, Arends J. Effect of sodium hypochlorite treatment on remineralization of human dentin in vitro. *Caries Res* 1996; 30:218–224.
47. Sakae T, Mishima H, Kozawa Y. Changes in bovine dentin mineral with sodium hypochlorite treatment. *J Dent Res* 1988; 67:1229–1234.
48. Frankenberger R, Kramer N, Oberschachtsiek H, Petschelt A. Dentin bond strength and marginal adaptation after NaOCl pretreatment. *Oper Dent* 2000; 25:40–45.
49. Perdigão J, Lopes M, Geraldini S, Lopes GC, Garcia-Godoy F. Effect of a sodium hypochlorite gel on dentin bonding. *Dent Mater* 2000; 16:311–323.
50. Lai SCN, Mak YF, Cheung GS, Osorio R, Toledano M, Carvalho RM. Reversal of compromised bonding to oxidized etched dentin. *J Dent Res* 2001; 80:1919–1924.
51. Yiu CKY, Garcia-Godoy F, Tay FR, et al. A nanoleakage perspective on bonding to oxidized dentin. *J Dent Res* 2002; 81:628–632.
52. Degrange M. Nonvital teeth: a list of questions. *J Adhes Dent* 2001; 3:291.
53. Goldstein RE, Garber DA. Complete dental bleaching. Carol Stream, IL: Quintessence Publishing, 1995.

Reprint requests: Simone Deliperi, DDS,  
Via G. Baccelli, 10/b, 09126 Cagliari, Italy;  
e-mail: simone.deliperi@tufts.edu

©2005 BC Decker Inc

## COMMENTARY

### TWO-YEAR CLINICAL EVALUATION OF NONVITAL TOOTH WHITENING AND RESIN COMPOSITE RESTORATIONS

Howard E. Strassler, DMD\*

In recent years there has been a trend in dental practices to provide esthetic services. One of the most significant changes has been in the area of tooth whitening. Although bleaching is not new, the many different methods of delivery have expanded. This article presents the reader with a return to the roots of bleaching, a clinical evaluation of the lightening of shade for discolored endodontically treated teeth. The authors take a unique perspective in not only evaluating the clinical performance of a nonvital tooth-bleaching technique, but by also addressing how the use of a conservative adhesive resin composite technique can restore an endodontically treated tooth without the need for posts and full-coverage restorations.

Discoloration of endodontically treated teeth is usually associated with trauma. The discoloration is an intrinsic dentin stain that occurs because the trauma to the tooth causes a hemorrhage of the pulp into the dentinal tubules. The blood products remaining in the dentinal tubules and discolor over time, leaving the tooth with a darkened, usually yellow-brown appearance. For this study all the teeth treated were shade A3 on a Vita shade guide or darker and had at least one Class III or IV restoration with the endodontic access preparation. To maintain a coronal seal of the gutta-percha endodontic treatment, temporary and existing restorations were removed as was the gutta-percha endodontic filling to a level at least 1 mm below the cemento-enamel junction. The gutta-percha endodontic filling was then sealed and restored with a resin-modified glass ionomer placed only at the cemento-enamel junction to allow for access for the nonvital bleaching treatment.

The nonvital bleaching treatment used in this study, an inside/outside bleaching technique, has been described in the dental literature for patients that desire tooth whitening for not only the endodontically stained nonvital tooth but for the adjacent vital teeth as well.<sup>1-3</sup> Although these articles have been case reports, the current authors have provided the reader with a true clinical evaluation of the results of inside/outside bleaching with a 2-year recall. Whenever nonvital tooth bleaching is performed, there is always the concern that there will be a bleaching relapse and that the tooth discoloration will return. The authors' data support the technique by demonstrating statistically using a post hoc test that there was a significant shade change between baseline and 2 weeks and baseline and 2 years; although there was some minor shade rebound, there was no significant difference between the tooth shade change at baseline and 2 weeks and baseline and 2 years. Looking at the raw data, the shade changes for the 20 patients (25 teeth) treated and recalled was an average of 13.4 shades, with all shade changes being visually apparent when viewing the Vita shade guide.

The second portion of this study was the use of adhesive resin composite restorations to restore the existing Class III or IV preparations and access openings of the teeth. After 2 years, the microhybrid Vitaescence, placed using a total-etch technique with a single component adhesive, PQ1, and a pulse curing technique at the final increment, demonstrated excellence clinical performance using modified US Public Health Service criteria for the restorations.

This study is an important one because it supports the use of a combined inside/outside approach for tooth whitening. Also, clinicians need to reevaluate the trend for the need for posts and full-coverage restorations to restore endodontically treated teeth with small Class III and IV restorations and access openings, and consider the use of an adhesive composite restoration only.

#### REFERENCES

1. Poyser NJ, Kelleher MG, Briggs PF. Managing discoloured non-vital teeth: inside/outside bleaching technique. *Dent Update* 2004; 31:204-214.
2. Caughman WF, Frazier KB, Haywood VB. Carbamide peroxide whitening of nonvital single discolored teeth: case reports. *Quintessence Int* 1999; 30:155-161.
3. Settembrini L, Gultz J, Kaim J, Scherer W. A technique for bleaching nonvital teeth: inside/outside bleaching. *J Am Dent Assoc* 1997; 128:1283-1284.

\*Professor, Department of Endodontics, Prosthodontics and Operative Dentistry, University of Maryland Dental School, Baltimore, MD, USA